

## Posterior Ridge Augmentation to Facilitate Cylindrical Endosseous Fixture Placement Followed by Prosthetic Reconstruction

by Gary O'Brien, D.D.S., El Gender, M.D., Ph.D., Tillman Moore, M.D.

### INTRODUCTION

Implant dentistry has evolved over the last ten years to become a mode of treatment with an exceptionally high degree of certainty.

Surgically, as well as prosthetically, the well-trained practitioner has the ability to treat most patients suffering from either total or partial edentulism. This reconstructive treatment modality has led to a documented international success rate well above 90 percent.<sup>1,5</sup>

However, a small percentage of crippled patients are denied this reconstructive surgery because they lack sufficient bone to accommodate endosseous implants. For these patients, many procedures have been developed to augment the anatomic structure to facilitate the placement of these substructures. This paper offers one approach to treating the atrophic posterior mandibular ridge, which is a challenge commonly faced in implant dentistry. This partially edentulous arch with bilateral edentulous areas located posterior to the remaining natural teeth is a Class I, Division B mandibular ridge from the Misch/Judy classification.<sup>6</sup>

### REVIEW OF LITERATURE

Augmentation of the oral structure with autogenous bone and synthetic bone substitutes in conjunction with endosseous implant placement has been widely documented in the literature.<sup>7,15</sup> Many applications for using freeze-dried demineralized allogeneic bone to repair osseous defects have been reported in the literature.<sup>16,22</sup> Contemporary research has shown that the resorbable demineralized bone induces osteogenesis by transforming fibroblasts into chondroblasts, resulting in ossification even when implanted into nonskeletal tissue.<sup>23</sup>

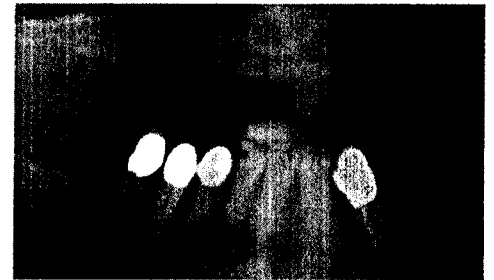In 1988 Masters outlined several applications of this material in conjunction with cylindrical endosseous implants. He states, "Today's clinician has a certain amount of

control over the quality and quantity of bone within the oral structures. Both the manipulation of autogenous bone and the judicious use of various synthetics and allographic materials can help the clinician restore the appropriate structures."<sup>24</sup>

In 1989, Whittaker et al. published the first eight month autopsy report of a human subantral augmentation using freeze-dried demineralized bone in conjunction with resorbable hydroxyapatite and simultaneous placement of titanium fixtures.<sup>25</sup> This report shows not only a well integrated fixture in both the area of the original bone and in the graft, but histological evidence of new bone replacing 80% of the graft material in 8 months. This paper confirms the work of Lozada and James from 1988 in Bone Grafting.<sup>26</sup> Recently other papers have documented the successful use of freeze-dried demineralized bone in the oral cavity in conjunction with implant dentistry and reaffirm the earlier findings.<sup>27,28</sup>

### MATERIALS AND METHODS

The patient was a caucasian female 47 years of age with an uneventful medical history. She was taking no medications at the time and was in good health. Clinical examination revealed a mandibular bilateral edentulous ridge (Figure 1). The remaining dentition, teeth numbers<sup>22,27</sup>, were periodontally sound and had no pre-existing restorations. A clinical evaluation utilizing panoramic radiographs indicated the right edentulous ridge provided ample bone height to accommodate endosseous implants. The left edentulous ridge, however, appeared inadequate for implant surgery and augmentation was indicated. The allogeneic materials used for the first phase of this procedure included freeze-dried demineralized bone powder with a particle size of 250 -500 microns (Pacific Coast Tissue Bank, Los Angeles, CA), sterile saline, and lincomycin in liquid form prepared to 300mg/ml. Prior to the surgical procedure, the Fddb was reconstituted in sterile saline for a period of 30 minutes. At this time



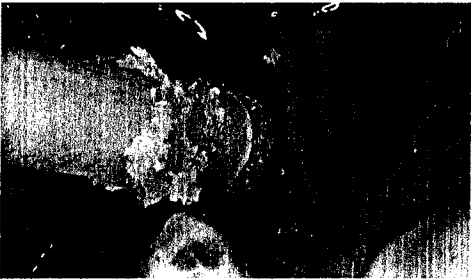**Figure 1** - A pre-surgical panoramic radiograph reveals adequate height of bone above the mandibular canal for installation of root form implants.

the excess sterile saline was removed by capillary action with sterile cotton fiber-free gauze. After the material was saturated with lincomycin for a period of 15 minutes, it was ready for surgical placement.

Penicillin V K 500 mg. (tabs 2 stat 1 qid until gone) was administered to the patient beginning 24 hours prior to surgery. The patient was scrubbed, draped for aseptic surgery, and lightly sedated with 5mg Valium<sup>TM</sup> orally. Bilateral mandibular blocks are performed using 6 ml. lidocaine and 1:100,000 epinephrine in a 27 gauge syringe. Using a number 15 Bard-Parker<sup>TM</sup> blade, a direct full thickness midcrestal incision was made through the mucoperiosteum to the crest of the ridge bilaterally to expose the bone in the areas of teeth number 17 -20 and 28 -32. Full thickness reflection revealed the posterior mandibular ridges and surrounding anatomical landmarks. The right ridge measured 4.4mm in its narrowest dimension and conventional surgical placement of three 3.75mm D ScrewVent Implants (Dentsply/CoreVent Implant Division, Encino, CA) was performed without complications (Figure 2).

The left ridge measured 2.3 -2.5mm in its widest dimensions. This confirmed the clinical evaluation indicating that it was inadequate for placement of any cylindrical endosseous fixture available on the market today. From these clinical findings, it was necessary to proceed with augmentation prior to implant installation surgery.

Using a surgical 170 tapered fissure bur,



**Figure 5** - Reconstituted FDDB is injected into the widened osteotomy with a stasis syringe.


the osteotomy was prepared following predetermined dimensions of radiographic findings to avoid impingement on the neurovascular bundle housed by the mandibular canal (Figure 3). The osteotomy extended along the crest of the ridge from the retromolar pad to directly above the mental foramen. Lateral releasing osteotomies were prepared on the buccal aspect of both the mesial and distal extensions to facilitate lateral displacement of the buccal cortical plate (Figure 4).

A bone chisel was used to fracture the buccal cortical plate. It was expanded using a Cryers™ elevator to create a void for placement of the prepared allogenic material. Care was taken to avoid periosteal stripping above the green-stick site. This was to assure adequate vascularity within the green-stick fracture.

Using a modified stasis syringe, the reconstituted allogenic material was transferred from the sterile dappen dish to the expanded osteotomy (Figure 5). It was critical at this point to avoid contamination and pack the graft material as densely as



**Figure 2** - (top left) The right posterior mandibular ridge after installation of three 3.75 mm pure titanium Screw-Vent Implants. **Figure 3** - (left) Preparations begin for a 2-2.2 mm wide osteotomy with a 170 fissure bur in the left posterior mandibular ridge. **Figure 4** - (above) The osteotomy prepared for a green stick fracture.




**Figure 6** - (above left) Clinical appearance prior to augmentation. **Figure 7** - (above right) 2 Months Postoperative: Soft tissue invagination along the midcrestal graft. **Figure 8** - (below right) Three Months Postoperative: Surgical reopening.

possible. Primary closure was then achieved by repositioning both the buccal and lingual flaps, and suturing with 3-0 black silk using a modified uninterrupted suture technique. The patient was then given postoperative instructions.

## RESULTS

### 3 Months Post-Augmentation: Clinical

Examination of the patient three months after surgery revealed clinical evidence of midcrestal invagination over the osteotomy site. An induration of the attached mucosa appeared along the scar line (Figures 6,7), raising concern that soft tissue was migrating toward the graft site. The area was surgically exposed (Figure 8). The graft site was highly vascular and tenaciously attached to the mucosa. The quality of the FDDB was somewhat spongy in nature and not adequately mineralized for preparation of the osteotomy. However, there was no soft tissue invagination beyond 2mm into



the graft. Samples were taken from the graft site for histological examination, then primary closure is achieved with 3-0 silk sutures.

### 3 Months Post-Augmentation: Histological

On the histological slides, approximately 80% of the sample was FDDB (Figure 9). Particles of FDDB powder were joined together into a single tissue conglomerate. In some areas the space between the particles of FDDB powder was filled with connective tissue. In the majority of locations, however, new, highly cellular bone joined the FDDB particles together

This bone still had some basophilic inclusions of cartilaginous matrix and there were a few remaining small islands of unresorbed cartilage. Slides stained with Picrosirius Red and examined in polarized light showed the presence of a small amount of collagen, type II. This represented a residual cartilaginous matrix (Figure 10).

**6 Months Post-Augmentation: Clinical**

Examination of the ridge indicated it had maintained its augmented width (Figure 11). Clinical palpation revealed the ridge to be very hard with healthy stippled mucosa over the augmented area. Upon surgical reflection, a new periosteum and cortical plate provided for easy manipulation of a full thickness flap (Figure 12). At this time, it was not tenaciously attached to the overlying mucosa. The quality of the graft was mineralized, but somewhat particulate in nature.

The particles of FDDB were surrounded by undifferentiated mesenchymal cells which had differentiated into chondrocytes and young osteoblasts.


However, it was mineralized sufficiently to allow for preparation of osteotomies and subsequent placement of root form implants.

Three osteotomies were prepared (Figure 13). One 16 mm Screw Vent Implant, which is 3.75mm in its major diameter, was placed just distal to tooth #22. The formerly 2 mm wide ridge in the vicinity of teeth #18 and #19 had been successfully augmented and expanded to 7 mm from buccal to lingual. Not only could it now accommodate a root form implant, but there was sufficient width to place two 4.5 mm CoreVent Implants, whose major diameter is 5.3 mm (Figure 14). Both primary sites of the grafted area were cored for histological examination (Figure 15).

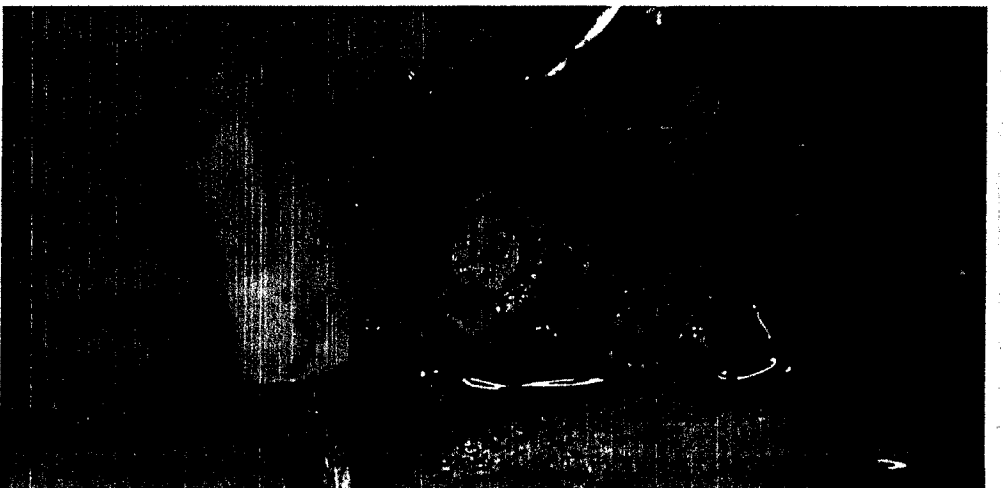

**Figure 15** - Core sample taken from graft site, 6 months post-augmentation.



**Figure 9** - (above left) H & E stained biopsy, 3 months post augmentation, of FDDB particles placed in osteotomy. **Figure 10** - (above right) Picrosirius Red stained biopsy, 3-months post-augmentation, of FDDB particles placed in osteotomy.



**Figure 11** - (below left) Augmented ridge maintained width at 6 months. **Figure 12** - (above) Surgical reflection at 6 months post-augmentation. **Figure 13** - (bottom) Osteotomy prepared in graft. **Figure 14** - (below right) Three endosseous implants installed in grafted ridge.



### 6 Months Post-Augmentation: Histology

Histological slides showed well-mineralized trabecular bone in 70 -80% of the surface area (Figures 16, 17). Trabeculae were covered with multiple osteoblasts and had numerous osteocytes situated within well defined lacunae. In some areas, trabecular bone contained small islands of residual FDDB. These could be distinguished from live bone by empty osteolytic lacunae. They were showing signs of continuous resorption by osteoblasts and simultaneous deposition of new bone.

### 6 Months Post-Augmentation 6 Months Post-Implantation

Six months after the implants were placed, the patient was scheduled for uncovering procedure (Figure 18). All the implants were very sound with approximately 1 -2 mm bone loss around the neck of both the Screw Vent and Core Vent Implants (Figure 19). The surrounding cortical bone was completely matured and not particulate in nature.

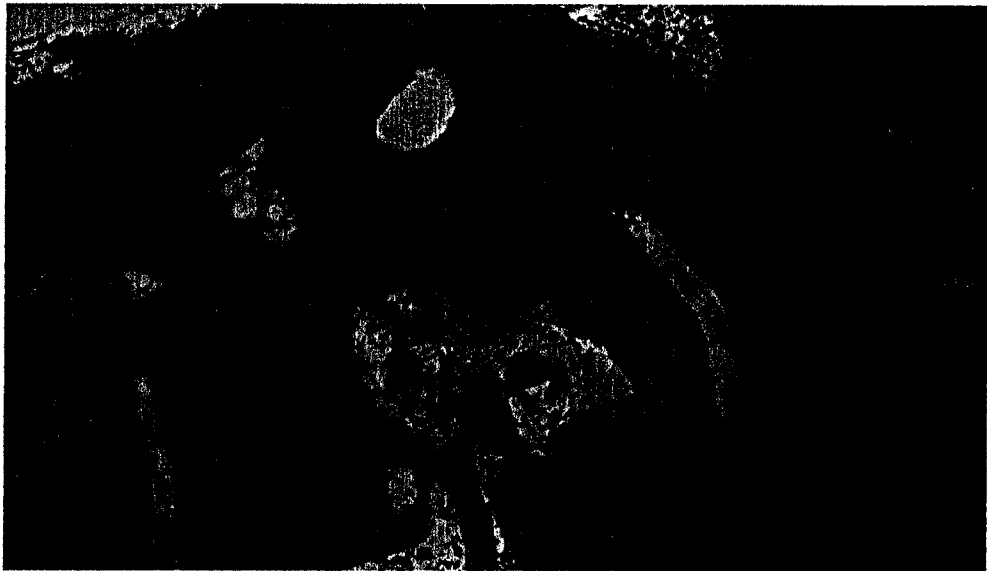
All three fixtures were rigid and elicited no mobility or pain upon manipulation. Impressions were made for indirect fabrication of custom cast posts and the final fixed prosthesis. At this point all three implants appeared clinically osseointegrated (Figure 20).

### 13 Months Post-Augmentation 7 Months Post-Implantation


The custom cast posts were cemented and final fixed prosthesis was permanently cemented (Figures 21, 22).

### 13 Months Post-Augmentation 7 Months Post-Implantation 6 Months After Loading

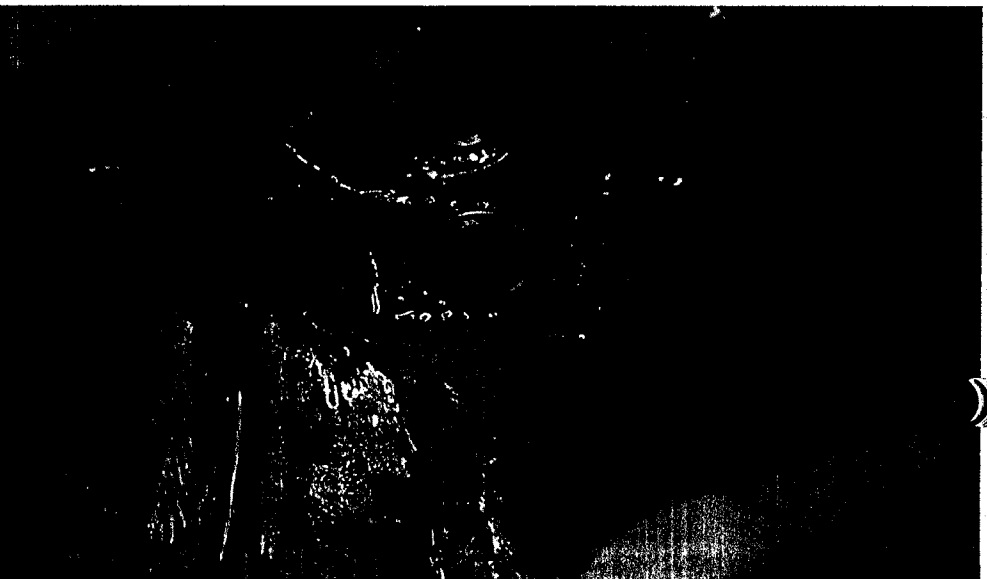
The prosthesis had successfully rehabilitated the edentulous ridge. Clinically, the bridge was not mobile and elicited no pain or discomfort upon mastication. Upon probing, a 2 -3 mm pocket depth was observed with no clinical inflammation or suppuration. At the base, the sulcus clinical attachment was observed. Radiographically there was no sign of fibrous encapsulation or existing pathology. Patient satisfaction of the resulting prosthesis was excellent. Radiographs revealed evidence of successful function and osseointegration 3 years after implant



**Figure 16** - (above) H & E stain, 6 months post-augmentation. **Figure 17** - (below) H & E stain, 6 months post-augmentation, showing new trabecular bridge.



**Figure 18** - (below) 6 months post-augmentation: uncovering.



# T H E I M P L A N T S O C I E T Y

insertion (Figure 21).


## CONCLUSION

This case demonstrates the use of a modified green-stick fracture technique to expand the posterior mandibular ridge from a 2.3-2.5mm width to a ridge width in excess of 7.0 mm. By positioning the buccal plate then filling the void with FDDB, new bone developed and provided adequate width for placement of 5.3 cylindrical endosseous implants. Histologically, this case demonstrates how the FDDB stimulates undifferentiated mesenchymal cells to differentiate in the interstitial spaces into young chondrocytes and osteoblasts. These begin to lay down the matrix for collagen type I and II, and eventually replaces the particles of the graft with new bone. At the 3 month surgery 70-90% of the graft were FDDB particles, and 30-10% interstitial cells. The work of many others over the past 30 years have given us the research information to use FDDB with confidence. The author has moved forward from this study to incorporate allogeneic synthetics, such as Osteomin™ (human ash), to provide a mineral reservoir, as well as lattice framework, for ingrowth of bone.


Semipermeable membranes, such as lamellar bone (Pacific Coast Tissue Bank) and Gore-Tex™, have been added to this technique to separate tissue and cell type. The combination of osteoinduction and osteoconduction, as well as mineral reservoir, has provided a more favorable bone quality at the six month uncovering. This more dense nature provides a better medium for immediate fixation.

The author has also employed fixtures coated with an osteoconductive non-absorbable ceramic in all graft situations to improve the bioactive nature of the grafted sites and increase the percentage of cubic millimeter surface area contact of implant to mineralized bone. Over the past six years, the author has clinically used this material in over 500 cases with differing applications to solve the Implant Dentistry's ever-present challenge: lack of available bone.

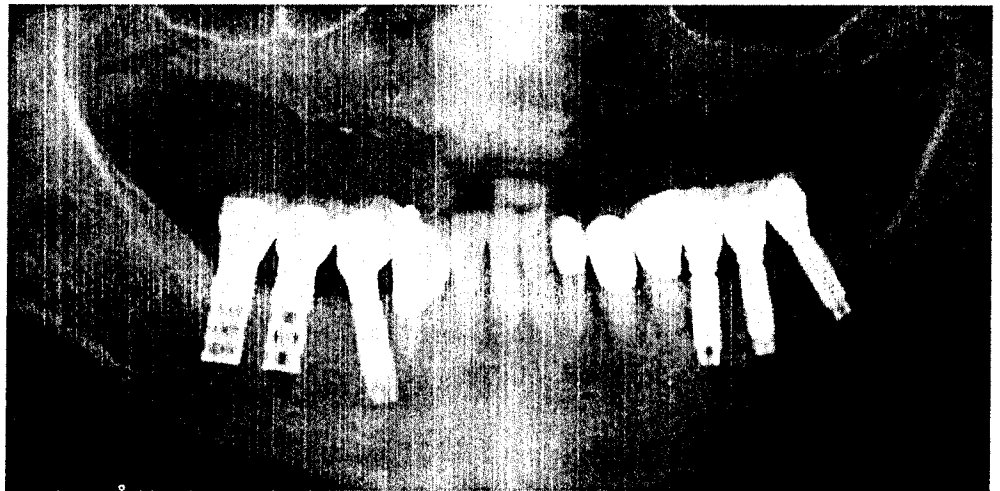
Further papers addressing the histological responses in a grafted situation to an HA coated fixture over the healing and loading phase will open new levels of understanding of the physiological process



**Figure 19** - 1-2 mm crestal bone loss around top of implant.



**Figure 20** - 2 weeks post surgical uncovering.



**Figure 21** - (right) Cemented posts, 2 weeks post-surgical uncovering. **Figure 22** - (above) Cemented prosthesis, 2 weeks post-surgical uncovering.

involved in this clinically successful situation. ■


Gary O'Brien, D.D.S., is in private implant dentistry practice in Glendale, California. He is Surgical Director of the Core-Vent Implant Institute and provides advanced education and surgical training through the Southern California Implant Institute.

Tillman M. Moore, M.D., is Chief, Orthopaedic Oncology and Director, Bone Bank, Orthopaedic Hospital, Los Angeles, CA, and Professor of Clinical Orthopaedics, new Emeritus, University of Southern California, School of Medicine.

El Gendier, M.D., Ph.D., is Research Associate Biochemistry Laboratory, Bone and Connective Tissue Research program, Orthopaedic Hospital of Los Angeles; Clinical Professor of Orthopaedic Surgery of USC School of Medicine; and Executive Director of Pacific Coast Tissue Bank.

## REFERENCES

- Adell R, Lekholm B, Rockler B, Branemark P-I: A 15-year study of osseointegrated implants in the treatment of the edentulous jaw. *Int J Oral Surg* 1981;10: 387-416.
- Patrick D, Zosky J, Lubar R, Buchs A: The longitudinal clinical efficacy of Core-Vent dental implants: a five-year study. *J Oral Implantol* 1989;15: 95-103.
- Kent J, Block M, Finger I, Guerra L, Larsen H, Misiek J: Biointegrated hydroxylapatite-coated dental implants: 5-year clinical observations. *JADA* 1990;121: 138-144.
- Buser D, Weber H, Bragger U: The treatment of partially edentulous patients with ITI Hollow-Screw implants. *Int J Oral Maxillofac Implants* 1990;5: 165-174.
- Kirsch A, Ackermann KL: The IMZ osteointegrated implant system. *Dental Clinics of North America* 1989;33: 733-739.



- Misch CE, Judy KWM: Classification of partially edentulous arches for implant dentistry. *Int J Oral Implant* 1987;4: 7-12.
- Hall M, Turner G: Bone graft augmentation in preparation for dental implants: discussion and case reports. *Today's FDA* 1989;1: 3C-5C.
- Judy K: Multiple uses of resorbable tricalcium phosphate. *New York J Dent* 1983;53: 401-402.
- Kahnberg K-E, Nystrom E, Bartholdsson L: Combined use of bone grafts and Branemark fixtures in the treatment of severely resorbed maxillae. *Int J Oral Maxillofac Implants* 1989; 4: 297-304.
- Wagner JR: A clinical and histological case study using resorbable hydroxylapatite for the repair of osseous defects prior to endosseous implant surgery. *J Oral Implantol* 1989;15:186-192.
- Smiler DG: Osseointegrated implants in sinus lift surgery in patients with severe resorption of the maxilla. *Implant Digest* 1988; Summer.
- Smiler DG, Doritch V: Treatment of the atrophic maxilla with sinus-lift grafting and implants. *Implant Digest* 1989; Fall.
- Misch CE: Maxillary sinus augmentation for endosteal implants: organized alternative treatment plans. *Int J Oral Implantol* 1987;4:49-57.
- Ashman A: Synthetic bone and implants: a winning

CONTINUED ON PAGE 16